

High Brachial Artery Bifurcation Clinical finding in Cadaveric Specimen by Medical Students During Internship

Giulia Garcia Pedrão¹; Thales Vinicius Candido da Silva²; Paulo Eduardo Novelini³; Beatriz Ferratone Magalhães²; Danilo Anderson Pereira²; Carolina Maria Favarim Neujorks²; Rogério Rodrigo Ramos^{4,5,6*}

¹Medical School, União das Faculdades dos Grandes Lagos (UNILAGO), São José do Rio Preto, SP, Brazil.

²Medical School, Universidade Nove de Julho (UNINOVE), Bauru, SP, Brazil.

³Medical School, Universidade Brasil (UB), Fernandópolis, SP, Brazil.

⁴PhD, Department of Human Anatomy and Medical Residency Program in General Surgery in Anatomy for Residents, Universidade Brasil, Fernandópolis, SP, Brazil.

⁵Bentham Science Ambassador, Fernandópolis, SP, Brazil.

⁶Nursing School, Centro Universitário de Santa Fé do Sul (UNIFUNEC), Santa Fé do Sul, SP, Brazil.

*Corresponding author:

e-mail address: rogerio.enfer@gmail.com tel. +55 17 3465 4200

Abstract

The high brachial artery bifurcation is an anatomical variation found in the arm segment. Although it does not present any alteration in the arterial blood functionality, it is considered a common spot for vascular lesions during surgical interventions that consist of the absence of anatomical knowledge. The research objective was to describe the high brachial artery bifurcation found in a cadaveric specimen from the anatomy laboratory as well as its main anatomoclinical aspects. Twenty-six upper limbs were investigated and dissected from the Universidade Brasil's Human Anatomy Laboratory, SP. These were formalized cadaveric specimens from both sexes. During upper limb dissection, arterial anatomical variations were observed in a single-arm segment. The variation was unilateral in the left hemisphere. The clinical findings were high brachial artery bifurcation and a rare case of the radial artery in the medial path, as well as an ulnar artery with a lateral path in the arm median third. It is clear that the understanding of anatomy and anatomical variations patterns is of utmost importance and a requirement for surgery, so surgeons need to be aware of clinical, anatomical, and arterial variations data, avoiding vascular lesions during the surgical interventions. Dissection is an important learning tool for students and resident doctors. It is suggested the use of dissection as a pedagogical resource to acquire skills in surgeries during internship and also to improve the anatomical variation cognition of upper limbs.

Keywords: Anatomoclinic Understanding; Surgery Skills; Dissection; Brachial Artery Anatomical Variation; Radial Artery; Ulnar Artery.

1. Introduction

The brachial artery, the main vessel by upper limb irrigation, originates in the axillary artery at the lower edge of the round major muscle, exhibits a path in the arm medial portion, at the distal end it extends to the anterior side, in the cubital fossa it is divided into two terminal branches (Figure 1), in radial and ulnar arteries^[1,2]. However, anatomical variations are assessed in the arm segment, occurring mostly in radial and ulnar arteries^[3], while variation in the brachial artery is less common^[4]. Still, the morphological variation of the brachial artery is uncommon, the bifurcation is evidenced at a higher point than the usually found, called this anatomical variation of high brachial artery bifurcation^[5] (Figure 2). It stands out during the teaching to medical students and resident physicians who glimpse the surgical specialty, the arterial variation is often found during cadaveric dissections in human anatomy laboratory and surgical interventions.

This shaping has major clinical implications, as the arm is a frequent injury area and is involved in many surgical and invasive procedures^[6]. It is important to emphasize that the absence of surgical skills, the patient's hemodynamic stability, and especially the anatomical knowledge, can hinder the surgery outcome, knowing that the anatomoclinic understanding and surgical skills are prerequisites for surgery.

Given this complexity, the study brings evidence to update and improve anatomical and clinical knowledge to resident doctors, especially to medical students who are taking disciplines like Human Anatomy, Morphophysiology, Surgical Technique, and the Medical Internship, since it is notorious the scholars difficulties regarding the cognitive aspects of learning and understanding the anatomical arterial variation. Thus, the research objective was to describe the high bifurcation of the brachial artery found in cadaveric specimens of the anatomy laboratory and its main anatomoclinical considerations.

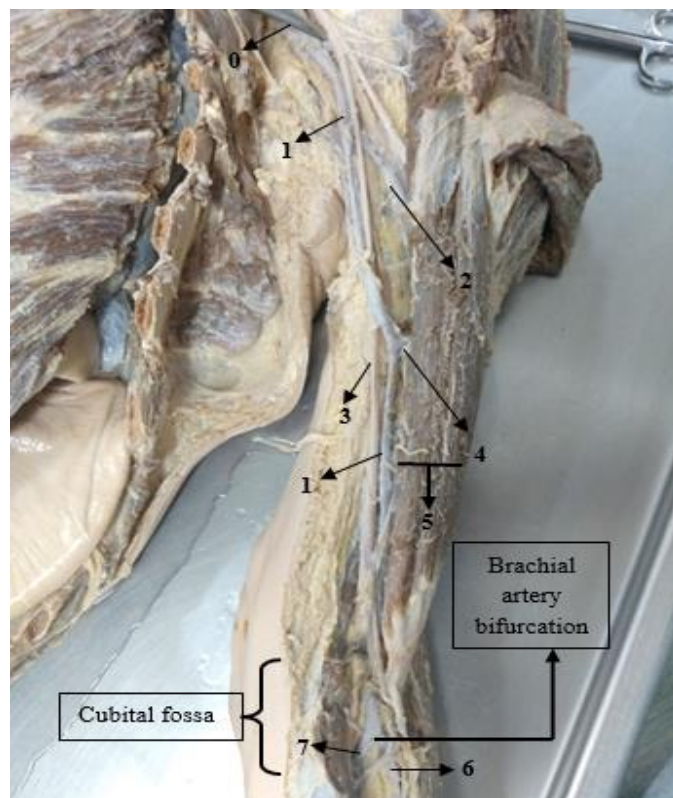


Figure 1. Brachial artery and its arterial branches with cubital fossa bifurcation. Legend: (0) the instrument pointing to the humerus circumflex artery, branch of the axillary artery; (1) brachial artery; (2) deep brachial artery; (3) median nerve; (4) superior ulnar collateral artery; (5) biceps brachial muscle; (6) radial artery and (7) ulnar artery.

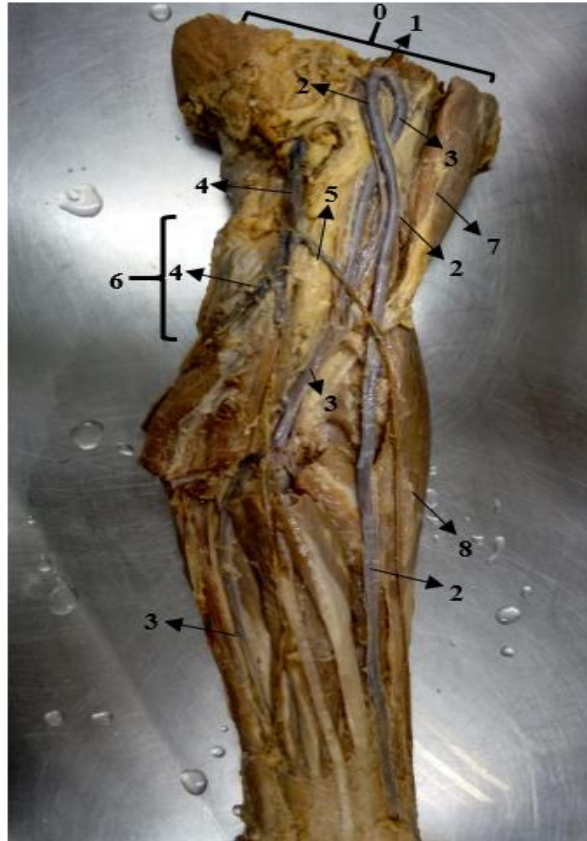

Figure 2. Brachial artery high bifurcation. Legend: (0) arm mid-third cross-section; (1) brachial artery bifurcation in arm mid-third; (2) radial artery; (3) ulnar artery; (4) basilica vein; (5) middle elbow vein; (6) cubital fossa; (7) biceps brachial muscle; (8) brachioradialis muscle.

2. Materials & Methods

The samples consisted of 26 upper limbs from the Universidade Brasil's Human Anatomy Laboratory, Fernandópolis Campus, SP. These are formolized cadaveric specimens of both sexes. The samples were used under Law 8501, November 30th of 1992, which stipulates the use of unclaimed cadavers for study or scientific research purposes. Inclusion criteria covered cadaveric specimens with an anatomical variation of the brachial artery and its terminal branches. Anterior, posterior, lateral, and medial sides of the arm and forearm dissections were performed to visualize the blood vessels.

3. Results

During the dissection of the human specimen, stored in the Universidade Brasil's Anatomy Department, it was possible to visualize and identify the arterial vessels anatomical variation in the arm

segment. Of the 26 limbs analyzed, only 1 left hemisphere upper limb was found to have a brachial artery high bifurcation (Figure 2) in the arm mid-third part. In addition to the high bifurcation, it was found a rare anatomical variation of the radial and ulnar arteries, the radial artery with a medial path in the arm mid-third part, as well as the ulnar artery with a lateral path (Figure 2), unusual case of the paths reported in the literature and in the clinic. For arterial pathway comparison, two male specimens were utilized, Figure 1 showing the arteries without anatomical variation, and Figure 2 illustrates the brachial artery high bifurcation.

4. Discussion

The arterial web clinical anatomy of the upper limb begins with the brachial artery (BA). Figure 1 shows that the BA has its origin from the axillary artery, with a descending path, in the upper third of the arm medially follows the median nerve, in the middle one crosses the median nerve in a lateral direction, then medially follows the biceps brachial muscle and ends in the cubital fossa, bifurcated into radial and ulnar arteries, considered brachial artery terminal branches^[7,8]. In the same Figure, two arterial branches are observed, the deep brachial artery and the superior ulnar collateral artery. It is important to note that the deep brachial artery and the ulnar collateral arteries are important vessels because they exhibit connections with branches of the radial artery, ulnar artery, and common interosseous, forming periarticular anastomoses of the elbow. The clinical aspects of the arterial network of Figure 1, present similar data from the authors Epperson et al.^[1], Mostafa et al.^[2], Drake et al.^[7], and Moore et al.^[8], indicating that the data are reliable and up-to-date.

In Figure 2, the limb cross-section was observed in the arm mid-third part. The cross-section location shows the terminal portion of the Brachial Artery with two artery releases, the radial and the ulnar. With the origin of the radial and ulnar arteries in the arm mid-third, this arterial web exhibits BA anatomic variations, a known clinical characteristic of high brachial artery bifurcation. Another point found in the Figure was the radial artery with medial path and the ulnar artery with lateral path, as in this case it is a rare event, these clinical aspects being divergent from the studies of Madhyastha et al.^[6], Moore et al.^[8], and Sieger et al.^[9]. However, these blood vessels alter their paths in the lower third of the arm, the radial artery crosses the ulnar artery anteriorly in a lateral direction, following the biceps medial edge brachial and brachioradialis muscle, following to the radiocarpal articulation^[10]. For Standring^[11], the ulnar artery appears at the level of the radial incisura of the ulna in the cubital fossa. This blood vessel leaves the cubital fossa, going deep in the pronator round muscle, and runs through the forearm between the flexor carpi ulnaris and the flexor digitorum profundus, following the wrist, ending at the superficial palmar arch. The radial artery leaves the cubital fossa, crossing laterally the forearm, following the brachioradialis muscle to the deep palmar arch.

An anomaly of the deep brachial artery (DBA) was found in the Madhyastha et al.^[6] research, presenting the origin of the posterior circumflex humeral artery (PCHA). It should be evidenced that the PCHA usually originates in the axillary artery third part and the DBA is an important collateral branch of the brachial artery that is anastomosis with recurrent radial and interosseous artery in the elbow region. The authors reported that the brachial artery high bifurcation was found in the upper third of the arm about 4

cm distal from the lower edge of the round major muscle. The brachial artery terminal branches descended parallel, deeply to the biceps brachial muscle. In the region of the elbow, the radial artery went through the cubital fossa, while the ulnar artery went deeply through the round pronator muscle. It is important to emphasize that arm arterial variations can cause erroneous blood pressure readings due to the presence of two arteries.

Sieger et al.^[9] found three less frequent cases. The first case was the bilateral brachial artery high bifurcation in each arm proximal third part. It is worth pointing out that there are few commentaries in the literature about the high brachial artery bifurcation, when it is found in the literature, it is usually cited in a hemisphere body. Chakravarthi et al.^[3] explain that this arterial anomaly is probably due to induction and branching of primitive vascular plexus during embryogenesis. The second case is the ulnar artery, in the cubital fossa (right and left), the ulnar arteries medially crossed the median nerve, continuing the path superficially to the forearm flexor muscles. This condition is rare and can be easily confused with a vein, which is considered a clinically significant factor and accident risk in intra-arterial injections^[12,13]. The third case refers to the common interosseous artery. This blood vessel was found exiting the radial artery, deep into the forearm flexor muscles, and usually originates from the ulnar artery. This artery is considered important due to supplying the interosseous membrane and having anastomosis with DBA.

It is evident that the anatomoclinic knowledge and anatomical variations patterns are of extreme importance in the repair surgeries performance in the arm area, thus, the surgeons need to comprehend all the web and arterial anomalies, avoiding possible vascular lesions during the surgery. Another point that should be highlighted is the low publication rate of the high brachial artery bifurcation, this draws attention to the scarce local and international literature, therefore makes it impossible to train and improve professionals and, in addition, it is harder to make more accurate diagnoses and safer surgical interventions in the upper limb region.

5. Conclusion

Learning Anatomy and anatomical variations of the arteries is a mandatory requirement for planning invasive and surgical treatments since the lack of such knowledge can cause serious vascular lesions, especially errors during orthopedic and plastic procedures in the upper limbs. Therefore, the cadaveric dissection is an important tool for Anatomy learning and arterial anomalies, using it as a pedagogical resource to acquire surgical skills during the internship and also improve the surgical techniques of resident doctors. In case of doubt about arterial path alteration, pre-operative angiography is indicated, because it helps in the variant artery tracking and the discovery of its place of origin. With the low publication of studies on high brachial artery bifurcation and its clinical aspects, it is suggested more medical research and case reports in national and international journals.

CONFLICTS OF INTEREST

The authors declare no conflict of interest.

References

- [1] T.N. Epperson and M. Varacallo, Anatomy, shoulder and upper limb, brachial artery. [Updated 2020 Aug 15]. In: StatPearls [Internet]. Treasure Island (FL): StatPearls Publishing; 2020.
- [2] E. Mostafa, O. Imonugo and M. Varacallo, Anatomy, shoulder and upper limb, humerus. 2020 Aug 10. In: StatPearls [Internet]. Treasure Island (FL): StatPearls Publishing; 2020.
- [3] K.K. Chakravarthi, S. Ks, N. Venumadhav, A. Sharma and N. Kumar, Anatomical variations of brachial artery - its morphology, embryogenesis and clinical implications. *J Clin Diagn Res.* 2014;8(12):AC17-20.
- [4] C. Cherukupalli, A. Dwivedi and R. Dayal, High bifurcation of brachial artery with acute arterial insufficiency: a case report. *Vasc Endovascular Surg.* 2008;41(6):572-574.
- [5] Tsoucalas G, Eleftheriou A, Panagouli E, High Bifurcation of the brachial artery: An embryological overview. *Cureus.* 2020;12(2):e7097.
- [6] S. Madhyastha, S.R. Nayak, A. Krishnamurthy, S. D'Costa, A.A. Jose and K.M.R. Bhat, Case report of high origin of radial, ulnar, and profunda brachii arteries, its clinical implications and review of the literature. *J Vasc Bras.* 2009;8(4):374-378.
- [7] R.L. Drake, A.W. Vogl and A.W.M. Mitchell, Gray's anatomia clínica para estudantes. 3 ed. Rio de Janeiro: Elsevier, 2015.
- [8] K.L. Moore, A.F. Dalley and A.M.R. Agur, Moore anatomia orientada para a clínica. Rio de Janeiro: Koogan, 2019.
- [9] J. Sieger, L. Patel, K. Sheikh, E. Parker, M. Sheng and S. Sakthi-Velavan, Superficial brachioulnar artery and its clinical significance. *Anat Cell Biol* 2019;52(3):333-336.
- [10] J. Sobotta, Atlas de Anatomia Humana. 24 ed. Rio de Janeiro: Guanabara Koogan, 2018.
- [11] S. Standring, Gray's Anatomy: The anatomical basis of clinical practice. 42nd ed. New York: Elsevier, 2020.
- [12] S. D'Costa, B.M. Shenoy and K. Narayana, The incidence of a superficial arterial pattern in the human upper extremities. *Folia Morphol (Warsz)* 2004;63(4):459-463.
- [13] D. Casal, D. Pais, T. Toscano, T. Bilhim, L. Rodrigues, I. Figueiredo, S. Aradio, M. Angélica-Almeida and J. Goyri-O'Neill, A rare variant of the ulnar artery with important clinical implications: a case report. *BMC Res Notes.* 2012;5:660.