

THE ROLE OF THREE-DIMENSIONAL CORTICO-BASAL GANGLIA- THALAMIC AND CORTICO-PONTO-CEREBELLAR PATHWAYS MODELS AND MULTIMODAL TEACHING IN MEDICAL EDUCATION

Victor Araújo, Isadora Mônica Ponte de Oliveira, Alexandre Almeida da Silva, Bianca Araújo Vieira, Rafaella Iughetti da Costa, Aline Moreira Lócio, João Pedro Benati, Beatriz Coutinho, Romina Andrea de Arruda Mourão, Leandro Freitas, Júlio dos Santos

Conflict of interest

The authors declare that they have no conflicts of interest. All authors read and approved the final manuscript.

Abstract

Introduction: The COVID-19 pandemic came with impasses, one of them in the educational area, creating numerous barriers. During this period, the access to traditional study methodologies became impracticable, causing some difficulties in the comprehension of some subjects for healthcare students. Therefore a 3D model was elaborated as a learning facilitator, whose main goal was to help healthcare students in the understanding of the voluntary motor movement, addressing the cortico-basal, ganglia-thalamic and cortico-ponto-cerebellar pathways, since the observation in cadavers is not possible. **Objective:** evaluate the impact of the 3D models in the teaching-learning process and present the comparison and the effects of using a biscuit model and the plastinated cadaveric pieces in the multimodal teaching of human anatomy. **Methods:** this study involved 47 students from the Physiotherapy course. A prototype was developed using biscuit dough, wood, polystyrene and paint and it illustrated in special dimensions the pyramidal tract and the cortico-basal, ganglia-thalamic and cortico-ponto-cerebellar pathways. The participants performed identical tests before and after the display of the different methodologic resources, 3D model and multimodal, where they were randomly grouped and divided. **Results:** It was verified that in spite of the greater number of correct answers in the post-test form, there was not, in fact, a significant statistical difference ($p=0,654$) between the participating groups, which states the necessity of developing an alternative approach and a more significant sample. A significant statistical difference was observed ($p<0.001$) when comparing the students' post-test knowledge with their pre-test knowledge when both methodologies were used, setting a multimodal approach, which is an alternative strategy that promotes a better development in teaching and learning. **Conclusion:** In our study, the teaching with cadaveric pieces ($p=0.010$) and the use of the 3D model singly ($p=0.006$) and the multimodal model ($p<0.001$) obtained similar results statistically. Therefore, the professors must choose the teaching methodology based on their aim and not for the intrinsic qualities in each method.

Keywords: Three-Dimensional Printing, Plastination, Teaching, Neuroanatomy, COVID-19.

1. Introduction

In January 2020 the World Health Organization (WHO) publicly declared a public health emergency of international importance due to the fast proliferation of the Sars-Cov-2 in some countries. Later, on March 11, 2020 the WHO declared the Covid-19 cases as a pandemic because of the global dissemination of the virus (1). Therefore, this event brought numerous changes in the population's habits, for example the use of masks and the social distancing, being the most viable alternatives to diminish the propagation of the virus (2). Besides, a lot of presential activities, such as educational ones, were temporarily suspended, so the educational institutions implemented remote teaching to guarantee the continuity of the educational development, accelerating the education's digitalization process (3).

Therefore, the practical teaching of neuroanatomy, discipline of great relevance to the health area courses, such as medicine, nursing and physiotherapy, was interrupted and the practical classes could gradually be resumed only after the decrease in the transmission rates and in the number of deaths secondary to COVID-19. Due to this, the learning deficit of practical neuroanatomy is clear during this remote teaching period, because of the difficulty to develop methodologies that could facilitate the learning of this discipline (4). Thus, it is fundamental that, with the return of the practical activities, the students can learn and understand, in fact, the subjects related to this discipline by using traditional methods, such as dissecting cadavers, and alternative ones, including 3D printing, virtual reality and 3D atlas (5).

The cadaveric pieces can be preserved for studying and research with formalin, glycerine or plastinated. Plastination is the most modern and lasting method of preservation of anatomic pieces and was developed by Dr. Von Hagens through a technique that replaces water and lipids for polymers, such as polyester, silicon and epoxy (6). This process is performed in four phases: fixation of the formaldehyde, dehydration, impregnation of the used polymer and its hardening (7).

Although the plastinated pieces are more durable, easy to transport and contribute to the anatomy teaching (8), such high complexity technique demands a good laboratory infrastructure for the institutions, aside from a high cost when it comes to these pieces' elaboration and a long period to produce them (4). Therefore, the need to utilize other ways besides plastination to study neuroanatomy, such as formalinized, glycerin and synthetic ones, is maintained.

Besides, the plastinated pieces don't highlight all the anatomic structures, mainly when studying the voluntary motor movement, performed by identification of the structures related to the stages of the movement in cadaveric pieces (9). That said, some students developed a model of the pyramidal and extrapyramidal system in 3D format utilizing biscuit dough to facilitate the visualization of structures that promote the voluntary motor movement and are imperceptible in cadaveric pieces, such as the corticospinal tract (5).

In this panorama, the confection of a structure made mainly of biscuit dough presents itself as being a ludic and alternative way in the process of teaching, besides having low financial cost (5). During the long creation process of the anatomical structures with biscuit, the students assimilate the name of the related neuroanatomical components with greater facility (10). Therefore, confectioning the pyramidal and extrapyramidal system's model was an alternative way to facilitate the understanding of this subject,

visualizing the macro and microscopic structures that compose it, diminishing the risks of destroying the cadaveric structures and enhancing its longevity (11).

Therefore, the confection of anatomical models from biscuit dough, wood, polystyrene and paint, molded to become the closest to reality, became an alternative way to visualize structures that are imperceptible in cadaveric pieces, although many students still prefer the utilization of the traditional model as an anatomy teaching methodology (8). Thus, the present study aims to compare the effects of the different approaches in the physiotherapy students's learning during a neuroanatomy, anatomy and a neurofunctional physiology class. For that, the students were divided in three groups in which the first group of the students utilized plastinated pieces, the second group used structures made out of biscuit dough and the third group utilized the cadaveric plastinated pieces and the 3D prototype that was created.

2. Methods

2.1 Model of the cortico-basal ganglia-thalamic and cortico-ponto-cerebellar pathways (3D)

The understanding of the cortico-basal, ganglia-thalamic and cortico-ponto-cerebellar pathways in the anatomical pieces is hard to visualize, taking into consideration that these pathways present themselves in the internal morphology of the brain. Therefore, a figure from the book *Neuroanatomia Clínica: Livro, Texto e Atlas* was chosen to illustrate in a didactic way some of these pathways through the extrapyramidal system.

Utilizing materials, such as wood, iron, biscuit, glue, wires and polystyrene, starting from a three-dimensional modeling based on a two-dimensional figure chosen as reference, the prototype began to be produced by the hands of the students involved.

Each structure of the model had its dimensions chosen so they could be properly proportional when united in the final prototype. Some parts of the model were hand-coloured so they could be more similar to the cadaveric structures, with the intention to facilitate apprenticeship. The confection time of the telencephalon, corticospinal tract, spinal cord, cerebellum, basal nuclei, lower motor neuron and muscle, lasted two weeks and demanded 3 kilograms of biscuit, 148 milliliters of paint, two polystyrene balls, a biscuit modeling tool kit, wires, a wood foundation 50x30 and an iron rod of 22 cm.

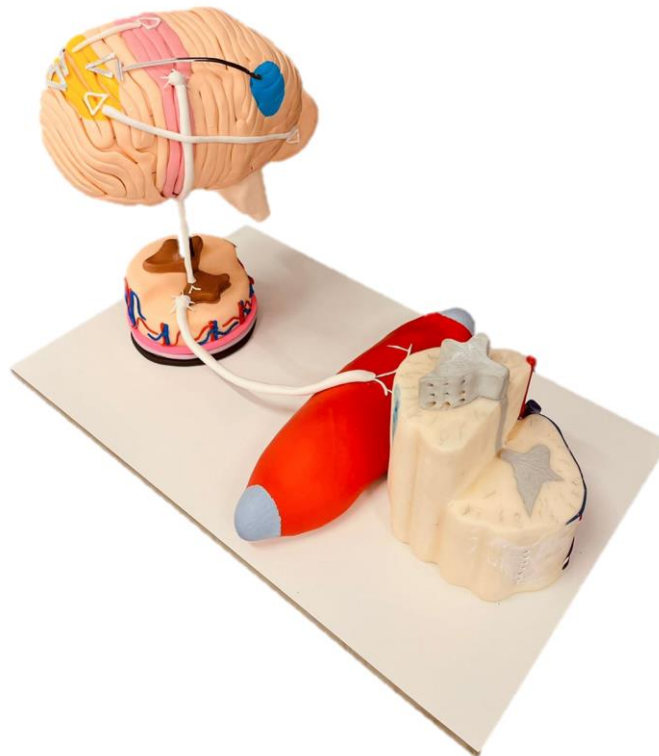


Figure 1. Three-dimensional model of cortico-basal ganglia-thalamic and cortico-ponto-cerebellar pathways.

2.2 Participants

The participants were physiotherapy students in the disciplines of human anatomy, neuroanatomy and neurofunctional physiotherapy from Centro Universitário Christus. The research was performed during the class of each discipline mentioned above, with that, the permission of the teacher responsible for the discipline was necessary so the application of the project could begin. The three physiotherapy classes had, in total, approximately 65 students, however only 49 students voluntarily accepted to participate and answered the pre-test form. Of the 49 participating students that were present during the interventions, 47 answered the post-test.

The students that didn't answer one of the two forms did not have their answers analyzed and included in the study. Therefore, the real number of participants is 47.

2.3 Ethics Committee

Firstly, the proposal was approved by the Ethics Committee in Research of Centro Universitário Christus under the protocol CAAE 57378822.5.0000.5049.

To execute this research the practice preconized in Brazil 2012, through the Resolution 466/12, that concerns the research involving human beings, which obeys the ethical principle of autonomy, mainly when it comes to consenting and enlightening the research's participants (Brazil, 2020), was taken into consideration.

In correspondence with the resolution cited above, highlighting that, under no circumstances, the name of the people involved in this research will be publicized, the participants’ data accepted the Informed Consent Form online.

2.4 Study Design

An experimental and quantitative study was executed with the intention of comparing the efficiency of the structures’ learning and the functions of the cortico-basal, ganglia-thalamic and cortico-ponto-cerebellar pathways using three different teaching models. The flowchart of the study is presented in figure 2.

The interventions were executed separately in 3 classes of physiotherapy students and in three different dates, adding up to 49 participating students; however, only 48 answered the pre-intervention questionnaire. After filling the pre-intervention formulary through Google Forms, an exposition-dialogue class was performed by the main researchers, about the extrapyramidal system, with a duration of 15 minutes. In the exposition-dialogue class, 49 participants were present and those were divided in three groups through sortition, which was executed before they answered the pre-intervention questionnaire, assigning 13 students to group 1 (cadaveric plastinated pieces), 13 students to group 2 (3D model) and 21 students to the intervention group 3 (multimodal teaching).

After the conclusion of the expositive class from group 1 with one of the main researchers and from group 2 with another researcher, both groups returned to the main room where the professor responsible for the discipline oriented them to answer the post-intervention questionnaire individually through Google Forms, whilst the two main researchers united the teaching methodologies in another room (cadaveric plastinated pieces and 3D model) to teach in an exposition-dialogue class for group 3. All the groups had approximately 23 minutes to answer the post-intervention questionnaire.

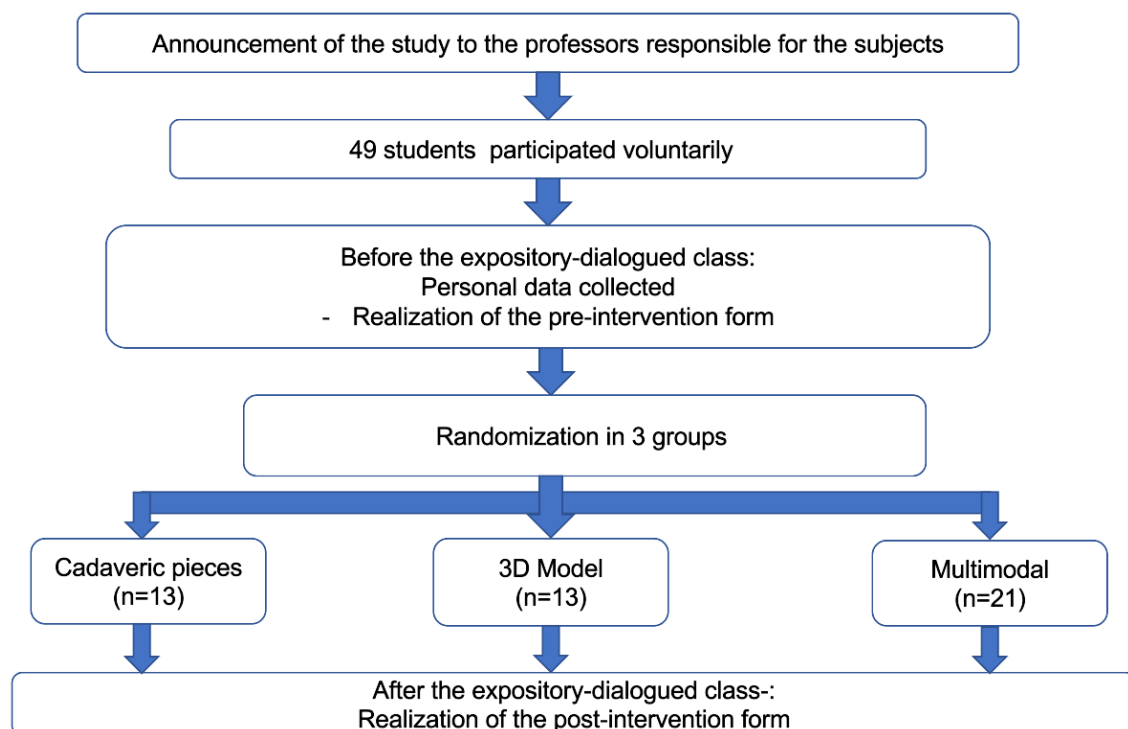


Figure 2. Flowchart of the study’s design.

2.5 Quiz Development

A total of 20 questions were created on neuroanatomy and pathophysiology related to the cortico-basal, ganglion-thalamic and cortico-pontine-cerebellar pathways. In order to create the quiz, functional bibliographic references were used, such as Functional Neuroanatomy by Angelo Machado and Clinical Neuroanatomy: book, text and atlas by Júlio Santos, in addition to scientific articles published in the last 5 years in databases and journals, such as PubMed, The New England Journal of Medicine, Nature Scientific Reports and The Cochrane Library.

The subjects covered in the quiz were indicated as the most relevant by the neuroanatomy professor, including: pyramidal system, extrapyramidal system, internal morphology of the spinal cord, morphology of the brainstem and cerebellum, ascending pathways and descending pathways, in addition to questions related to the clinical practice and associated with the anatomical knowledge of the aforementioned contents.

The 20 questions produced (table 1) for the elaboration of the questionnaire in Google Forms had an instructive and objective character, disposing of five options, of which one alternative was the correct one, these questions were used as pre-intervention and post-intervention containing the same questions, available in Portuguese and English.

2.6 Expository-Dialogue Class

After the execution of the pre-intervention form, all students participated in the class called “Voluntary Motor Movement!” taught by the principal researchers, in person at the Christus University Center. The expository-dialogue class was carried out in such a way that the principal researchers were separated with their respective group of students .

The class named “Voluntary Motor Movement” had the following learning goals:

- Demonstrate the neuroanatomy structures related to the voluntary motor movement.
- Functionally describe cortico-basal, ganglion-thalamic and cortico-pontine-cerebellar pathways.
- Understand the pathophysiology of diseases such as Cerebral Vascular Accident (CVA) and Parkinson's.
- These are the possible changes in the pyramidal system and extrapyramidal and the clinic changes.

In essence, after the intervention, the participants had a maximum time of 30 minutes to answer and finish with the submission of post-intervention form responses via Google Forms. During the time when the students submitted their answers, one of the principal researchers verified and analyzed the data received by Google Forms.

Table 1. Google Forms questions.

Upper motor neurons (UMN) are subdivided into several sectors in a somatotopic form, where each one has specific functions in the body. The pyramidal tract is the main pathway that transmits signals for motor behavior. Thus, injuries in this tract cause:	After performing the voluntary motor movement, the execution phase, it is necessary that this movement is refined and perfected. For this to happen it is necessary that specific receptors present in the muscle and muscle tendon send information back to the cortex through afferent pathways. Thus, it signs them which receivers are:	Voluntary motor movement is involved with the pyramidal and extrapyramidal systems, which are composed of several complex structures of the nervous system. Therefore, in relation to the complete stage of voluntary motor movement, mark the correct alternative:
Elastic Hypotonia, Hyperreflexia, Clonus and Babinski's Sign.	Muscle Spindle and Golgi Tendinous Organ (GTO).	Plan, Fix and Execute.
Plastic Hypertonia, Hyperreflexia, Clonus and Babinski's Sign.	Muscle Spindle and Nociceptors.	Plan, Correct, Execute and Recorrect.
Elastic Hypertonia, Hyperreflexia, Clonus and Babinski's Sign.	Muscle Spindle and Muscle Receptors.	Plan, Correct and Recorrect.
Plastic Hypertonia, Hyperreflexia, Clonus and Babinski's Sign.	Golgi Tendinous Organ and Nociceptors.	Fix, Plan and Execute.
Plastic Hypotonia, Hyperreflexia, Clonus and Babinski's Sign.	Muscle Spindle and Thermoreceptors.	Plan, Execute and Fix.
In relation to the corticospinal tract, answer: () It is responsible for carrying the information inherent to the primary somesthetic area. () It is responsible for sending information on the contraction and inhibition of agonist and antagonist muscles, respectively. () This tract is the only one that does not carry out the decussation. () The corticospinal tract is the main afferent system through which voluntary movements are initiated and performed.	Extrapyramidal involvement does not lead to paralysis like the pyramidal one, but to paucity or absence of movement, respectively hypokinesia and akinesia. Thus, one can observe a slowness in the execution of voluntary movements, especially at the beginning of the movement or when it is about to be completed. This condition is called:	The basal ganglia play an important role, as does the cerebellum in the process of voluntary motor movement. Therefore, sign the role of the base's nuclei in this process: Select the muscles that will be activated and inhibited for the process to occur.
F, F, F and F	Tetraplegia	Select the muscles that will undergo elastic hypertonia.
F, V, F and F	Paraplegia	Select the muscles that will undergo plastic hypertonia.
V, F, V and F	dysdiadochokinesia	Select the muscles that will undergo hypotonia.
F, V, F and V	bradykinesia	Select the muscles that will be agonists and antagonists
V, V, F and V	Diadochokinesia	
The penfield homunculus is superiorly nourished by the anterior cerebral artery. Injuries to this artery, such as in a cerebrovascular accident (CVA), can compromise the homunculus. Thus, sign the alternative that shows some of the inherent consequences of the involvement of this artery.	After the entire voluntary motor movement planning process, it is executed and finally the correction/refinement, the last step, begins to happen. Regarding the last stage of voluntary motor movement and the cerebellum respond:	The precentral and postcentral gyri are intrinsically related to motricity and sensitivity, as they are the primary areas. Regarding injuries in secondary areas, sign:
Deficit in the leg, foot and trunk, with paresthesia in the posterior part of the lower limb.	The inferior and lateral spinocerebellar tracts will send information to the brainstem in order to refine movement.	Injuries in the motor areas cause apraxias and in the sensitive areas cause agnosia.
Deficit in the arm, hand and trunk, with paresthesia in the posterior part of the lower limb.	The anterior and posterior spinocerebellar tracts will send information to the spinal cord in order to increase movement.	Injuries in the motor areas cause agnosias and in the sensitive areas they cause bradykinesia.
Deficit in the leg, arm and trunk, with paresthesia in the posterior part of the lower limb.	The anterior and posterior spinocerebellar tracts will send information to the spinal cord in order to increase movement.	Injuries in the motor areas cause agnosias and in the sensitive areas they cause apraxia.
Deficit in the leg, foot and genitalia, usually with paresthesia in the posterior part of the lower limb.	The anterior and posterior spinothalamic tracts will send information to the cerebellum in order to decrease movement.	Injuries in the motor areas cause apraxias and in the sensory ones too.
Deficit in the leg, foot and genitalia, usually accompanied by urinary incontinence.	The anterior and posterior spinocerebellar tracts will send information to the cerebellum in order to refine movement.	Injuries in the motor areas cause agnosia and in the sensitive ones too.
Broca's Aphasia is the reduction or absence of the ability to communicate through expressive speech. It is a condition usually diagnosed in patients with a history of stroke. The lobe of the brain injured in patients with this pathology is:	What is the name of the afferent pathway of the cerebellum, which helps correct movements in progress, as it provides the cerebellar cortex with details of the intention of each movement?	Agnosia is the ability to recognize sensory or sensory stimuli not specifically related to language elements. In relation to prosopagnosia answer:
occipital lobe	Pontocerebellar tenement route	It is the individual's inability to recognize words
temporal lobe	Olivocerebellar bundle	It is the individual's ability to perform fast movements
parietal lobe	Dorsal spinocerebellar tract	It is the individual's inability to walk
insular lobe	Vestibulocerebellar bundle	It is the individual's inability to recognize the facial features of family members
frontal lobe	Ventral spinocerebellar tract	It is the inability to perform alternate movements
Related to pyramidal and extrapyramidal systems analyze the following statements and correlate with their respective definition. () Tonic or clonic involuntary movements. () Rapid and sudden contractions involving isolated muscles or muscle fiber bundles. () Sudden, irregular, incomplete and aimless movements. () It is the abnormal increase in muscle tone, in which the muscle loses its ability to stretch, which can result in increased stiffness due to constant signaling of muscle contraction. I-Myoclonus II- Spasms III-Hypertonia IV- Choreic movements	Apraxia is the inability to perform a certain motor behavior previously learned during an injury in the secondary motor areas. Regarding the types of apraxia, correlate: () Patient is incapable of performing fine and delicate movements. () Inability to perform movements of the lips, mouth and jaw through an external command. () It is the inability to perform complex motor behavior with the non-paretic limb. I- Sympathetic apraxia. II- Kinetic apraxia of limbs. III- Oral apraxia.	Human movement is composed of some steps, these are related to the pyramidal and extrapyramidal system, with approximately 66.7% of this process carried out by the extrapyramidal system. Therefore, analyze the statements below and mark (V) for true and (F) for false. Plan and Execute are related to the extrapyramidal pathways. Correct and Execute are related to the extrapyramidal pathways. Plan, Correct and Execute are related to the extrapyramidal pathways. Plan and Correct are related to the extrapyramidal way and Execute the pyramidal way. Performing is exclusively related to the pyramidal way.
I, II, IV and III	I, II and III	
III, II, IV and I	III, II, and I	
IV, III, II and I	II, III and I	
II, I, IV and III	I, III and I	
I, II, III and IV	II, I and III	
Stroke causes loss of voluntary control of motor movements. The most common dysfunction in these situations is paralysis on one side of the body, conceptualized as:	The positive Babinski reflex is presented with an extension of the big toe and a fan opening of the other toes. Although common in neonates, the maintenance of this reflex in adults indicates neurological damage. Mark the neurological lesion where this sign can be seen.	Stroke (CVA) has two very important clinical phases, the refractory phase and the release phase. Regarding the refractory phase, answer: It is the acute phase of 3-4 weeks after the stroke and the patient has hypotonia, absence of the clonus, hyporeflexia, in addition to some other signs. It is the acute phase of 3 to 4 weeks after the stroke and the patient has hypertonia, clonus, hyperreflexia and some other signs. It is the acute phase of 1 week after the stroke and the patient has hypotonia, absence of clonus, hyperreflexia, in addition to some other signs. It is the acute phase of 3-4 weeks after the stroke and the patient has hypotonia, clonus, hyporeflexia and a positive Babinski sign, in addition to some other signs. It is the acute phase of 3-4 weeks after the stroke and the patient has hyperreflexia, clonus, hypertonia and positive Babinski's sign, in addition to some others.
Apraxia	Meningitis	It is the superior parietal gyrus
Hemiparesis	extrapyramidal lesion	It is the post-central gyrus
Aphasia	Corticospinal tract injury	It is the marginal turn
Hemiplegia	Cerebellum Injury	It's the angular turn
Dysarthria	Occipital cortex lesion	It is the pre-central gyrus

Intervention group 1: plastinated cadaveric pieces

It utilized two cadaveric pieces of the brain previously dissected and platinum, in order to facilitate the handling and locomotion of the pieces to the rooms outside the anatomy laboratory. The pieces had a sagittal cut to facilitate the internal visualization of some structures, such as the medial part of the brainstem, diencephalon and the internal part of the pre and post central gyrus. During the class with the plastinated pieces, the cortical and subcortical structures were identified, in addition to their functions related to voluntary motor movement, such as the cerebellum, basal ganglia, precentral gyrus, postcentral gyrus and brainstem.

In that regard, one of the responsible researchers demonstrated the cadaveric pieces and structures and also associated the possible lesions of these structures with the clinical practice, seeking to develop a reasoning focused on the possible clinic alterations, always following a pre-established script to address the issues relevant to the questionnaire. At the same time group 1 followed up the explanation with the cadaveric pieces, group 2 found itself having as an intervention the explanation using another methodology.

After 15 minutes of intervention, group 1 came back to the place where the professor responsible for the discipline was and started to answer the post-intervention questionnaire.

Intervention group 2: 3D model

The 3D model was presented to students participating in group 2 and then the researcher in charge started the class based on a pre-established script, to address issues related to post-intervention questionnaires. During the class the cortico-basal, ganglion-thalamic and cortico-pontine-cerebellar pathways could be observed in the 3D model, facilitating the association and the students' learning process of the voluntary motor movement.

In order to facilitate the visualization of pyramidal and extrapyramidal structures the student could assimilate the anatomy structure with its respective function, they were allowed to touch the 3D model structures, visualize the inner part, such as the basal ganglia, and develop linear reasoning following each step of voluntary motor movement.

Therefore, the researcher in charge of group 2 demonstrated physically in the 3D model the structures that could not be visualized in the cadaveric pieces due to the difficulty or even the impossibility of dissection of these structures, the model has exactly the intention of facilitating the teaching of these pathways, showing them physically.

After 15 minutes of intervention, group 2 came back to the place where the professor responsible for the subject was and started to answer the post-intervention questionnaire.

Intervention group 3: multimodal approach

In this group, two methodologies mentioned above were used, in a way that the participants received a multimodal approach: classical teaching with plastinated cadaveric pieces and the use of the 3D model with physical identification of the pathways related to voluntary motor movement.

This group received a 15 minute intervention, as did the others. After the intervention, group 3 came back to the place where the professor responsible for the discipline and started to answer the post-intervention questionnaire, each student in their respective chair using their cell phone or tablet.

2.7 Statistical Analysis

The evaluation analyzes the effect of the type of teaching methodology (group 1, 2 or 3) in relation to the scores obtained by the students before and after the evaluative questionnaire were expressed as mean \pm standard deviation. The evaluated data presented a non-parametric distribution. Nonparametric analysis for paired data from two categories (eg pre and post) were analyzed using the Wilcoxon test; when the data were grouped into three categories, the Kruskal-Wallis unpaired test was used followed by the Dunn's post-test. All tests were two-sided and considered to be statistically significant if the p value was ≤ 0.05 . SPSS v. 25.0 (SPSS, Chicago, Illinois, USA) was used for analysis.

3. Results

In the first moment, the data related to the students' sex is presented. Subsequently, the data was divided in two sections, one of them analyzed the performance pre and post-test of all the groups and the other one analyzed individually the performance of the participants within three different experimental groups.

In relation to sex, it was verified that, in the pre-test, 85,7% were females, while 14,3% were males. In the post-test, 81,6% were females and 18,4% were males (Table 2).

Table 2. Total number of students by sex who participated in the pre-test and post-test

Sex	PRE-TEST – PARTICIPANTS (49)	POST-TEST – PARTICIPANTS (47)
MALES	7 (14,3%)	7 (18,4%)
FEMALES	42 (85,7%)	40 (81,6%)
Total	49	47

Quiz (all methodologies)

The number of correct answers of the groups participating in the pre-intervention form was observed (figure 3). Results showed that there wasn't a meaningful statistical difference ($p=0.244$) between the groups, based on the knowledge level of the students who answered the pre-test form.

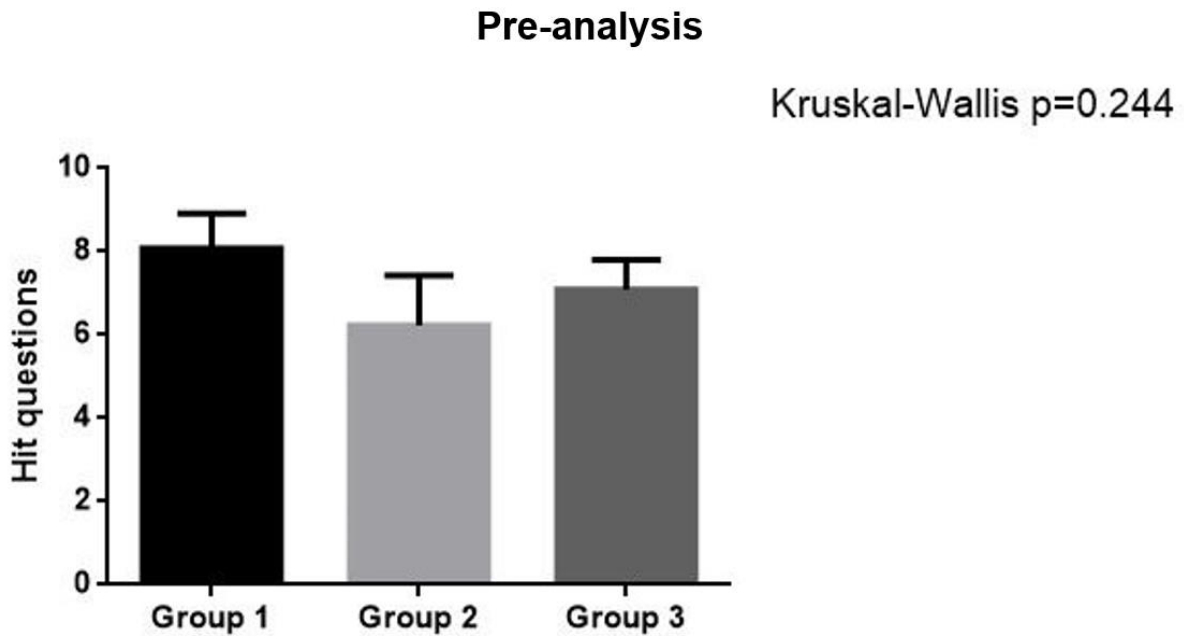


Figure 3. Comparison of correct answers during the pre-test from all the intervention groups. The Wilcoxon test was utilized for statistical analysis.

It was verified that, despite the higher number of correct answers in the post-test form (figure 4), there wasn't, indeed, a meaningful statistical difference ($p=0,654$) between the participants groups, indicating the necessity to develop an alternative approach and a more significant sample.

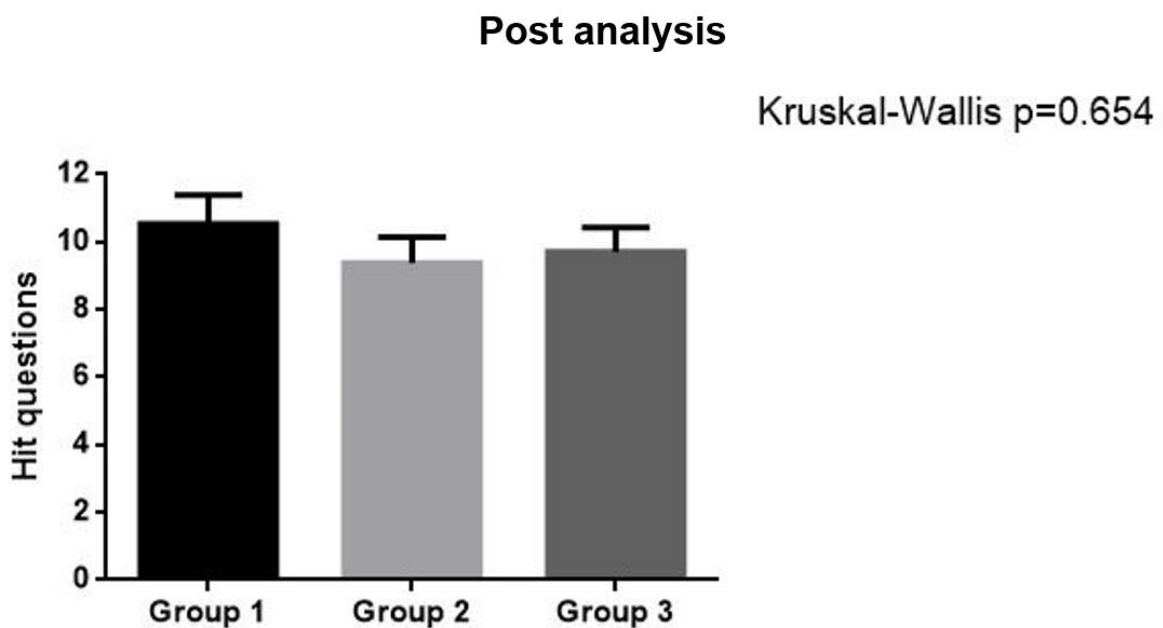


Figure 4. Comparison of correct answers during the post-test from all the intervention groups. The Wilcoxon test was utilized for statistical analysis.

3.1 Intervention group 1: plastinated cadaveric pieces

When individually analyzing group 1, it was observed (figure 5) that, after exposure to the methodology with plastinated cadaveric pieces during a class on the cortico-basal, ganglion-thalamic and cortico-pontine-cerebellar pathways, there was a significant difference ($p=0.010$) when compared to student's knowledge in the pre-test, that is, the participants managed to assimilate the content with the traditional resource used and retained the knowledge. This way, it was found that the use of plastinated brains is a valid strategy to promote learning.

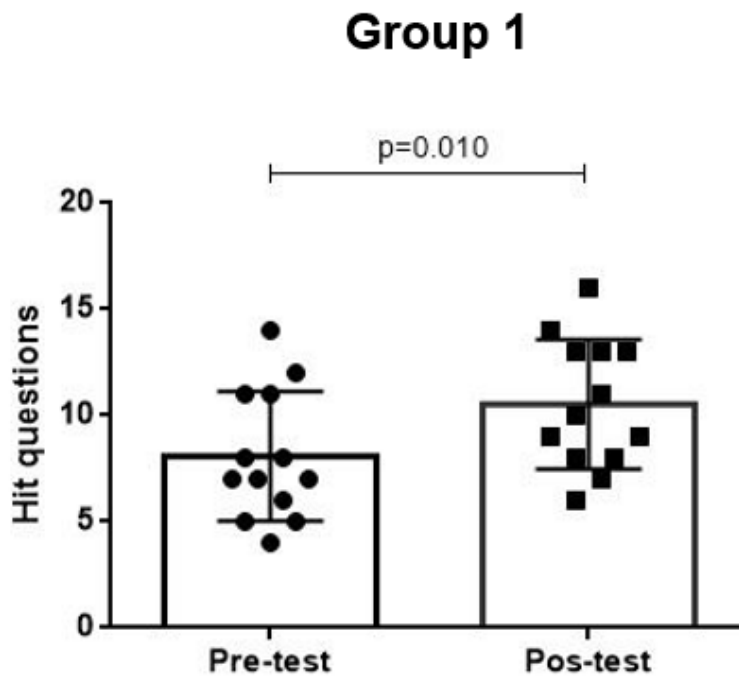


Figure 5. Comparison of correct answers during the pre and post-test from the students that had classes with the intervention group 1 (cadaveric plastinated pieces). The Wilcoxon test was utilized for statistical analysis.

3.2 Intervention group 2: 3D model

It was verified (figure 6) that, after applying the 3D model as a teaching methodology for the cortico-basal, ganglion-thalamic and cortico-pontine-cerebellar pathways, there was a significant difference ($p=0.006$) when compared to the number of correct answers in the post-test with the number of hits in the pre-test. Therefore, the students were able to learn with this methodological resource used and assimilated the acquired knowledge. This was, it is correct to affirm that the use of the 3D model is a strategy that promotes the teaching-learning process in a significant way.

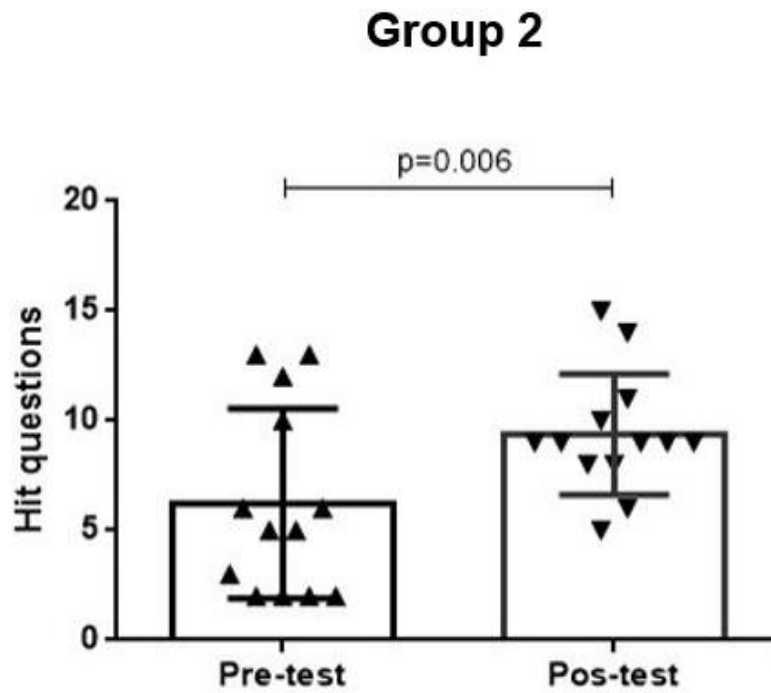


Figure 6. Comparison of correct answers during the pre and post-test from the students that had classes with the intervention group 2 (3D model). The Wilcoxon test was utilized for statistical analysis.

3.3 Intervention group 3: multimodal approach

It is observed (figure 7) that, after the utilization of cadaveric plastinated brains and 3D models in a simultaneous way with a multimodal approach during the class about the cortico-basal, ganglion-thalamic and cortico-ponto-cerebellar pathways, there was a statistically significant difference ($p < 0.001$) when comparing the students' knowledge post-test with the students' knowledge pre-test, which means that the students were able to learn with the utilized resource and assimilated the acquired knowledge. Therefore, it is concluded that, the utilization of both methodologies, which constitutes a multimodal approach, is an alternative strategy that promotes a better development in teaching and learning significantly.

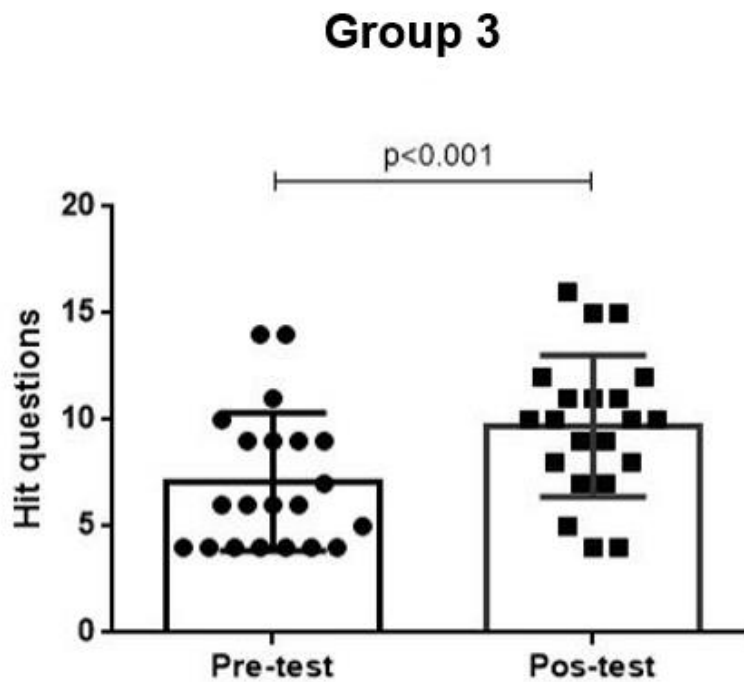


Figure 7. Comparison of correct answers during the pre and post-test from the students of the intervention group 3, whose class had a multimodal approach . The Wilcoxon test was utilized for statistical analysis.

4. Discussion

The study of the human body’s anatomy, with its traditional cadaver dissection techniques, contributes to the teaching and the primordial knowledges in the graduation of the health professionals, being considered the “base of medical sciences” (12), as prove of that, the present study evidenced that the students retain knowledge with the traditional model, proven by the difference when comparing the answers from the post-test and pre-test ($p=0.01$).

In this context, with the advent of the pandemy and the subsequent social isolation implemented in most countries, remote teaching emerged as an alternative to minimize damages in the student sphere. In this context, the professors came across the necessity of adapting to the new teaching model, providing an increase in the use and in the acceptance of new teaching methods (13), an example of that was the utilization of technologies as alternatives to the traditional study of anatomy trough dissecting cadavers, such as videos, online resources (3D atlas) and virtual reality. Thus the pandemic period highlighted the importance of utilizing creative, innovative and multimodal ways for the apprenticeship of anatomy (12).

As the cases and deaths associated with Covid-19 decrease and the practical activities are resumed gradually in the higher education, studies suggest that maintaining the multimodal strategies of teaching anatomy can be enveloping, interesting and of great value to the students, since it makes the practical classes more interactive and makes it possible for the student to retain knowledge (8), in consonance with the present study which demonstrated that the students were able to assimilate knowledge when the 3D models were used for teaching, proven by the difference between the pre-test and post-test answers ($p=0.006$).

Therefore, circumventing the accessibility challenges, the popularization of the three-dimensional printers made possible the creation of anatomical models below cost and without needing specialized labor, which contributes to the access of these innovative methods by students, professors and universities (14). Besides, researches evidenced that the 3D model has an important role in the study of complicated and detailed structures, such as the middle ear (15), orbital cavity (16), components of the temporal bone (17,18) and ventricular structures (19). Therefore, to stimulate active learning, studies suggest that the students create, manually, neuroanatomical models of specific structures and correlate them with clinical manifestations, generating curiosity and investigative behavior, since the investigation plays an important role in the process of teaching and learning (20).

In the present study, however, when comparing the study's participating groups in the pre and post-test forms it was observed that there was not, in fact, a significant difference between the methodologies. In this context, studies demonstrate that the cadaveric dissection is the most traditional and effective way of teaching the health professionals about anatomy (21). In counterpart, recent researches suggest that the use of 3D models in the preoperative between medical students and doctors facilitate the posterior surgical approach, facilitating the professionals' perspective (JASKA et al, 2021), thus, the use of the 3D models to visualize more complex anatomical structures is strongly increasing in the health area, being reported as one of the best current technologies for pre-op preparation and the surgical training of surgeons (23). Consequently, it is necessary that studies that analyze these alternative approaches are developed, with more intervention time and a more significant sample to obtain more reliable results.

Furthermore, in the neuroanatomy study, learning through physical pieces is fundamental, once it allows the recognition of structures of great importance. Yet, the use of 3D models in the elaboration of anatomical structures of relatively low cost becomes convenient for a better microanatomical visualization, such as the pathways and the tracts, providing an improved learning to the healthcare students. In this context, the association of the two methodologies, setting up a multimodal approach, appears as an alternative strategy that promotes student development and learning in a relevant way (24). However, the Wilson et al meta-analysis affirms that, when comparing the multimodal approach with the other pedagogical methods, that is, only 3D models, traditional dissection, plastinated pieces, the student scores were statically assembled (25).

In accordance, the present study found that the multimodal approach, utilizing cadaveric plastinated pieces to visualize the macroscopical structures associated with the 3D model for microscopical structures, contributes to the students' retention of knowledge, since the difference between the pre-tests and the post-test was significant ($p < 0.001$). However, the number of correct answers from the group that was exposed to the hybrid teaching was statistically equivalent to the other participating groups ($p = 0,654$).

5. Conclusion

The 3D model of the cortico-basal ganglia-thalamic and cortico-ponto-cerebellar pathways associated with the traditional teaching technique facilitates the assimilation of the basic anatomy even of the most complex structures of these systems. An intrinsic advantage of the 3D model is that, when compared to cadavers, the cost is lower, it is easier to transport and there are no ethical issues involved.

However, the cadaveric pieces, aside from promoting the apprenticeship of the human structure and function, develop ethical qualities, self-reflection and communication and interpersonal skills. In our study, the teaching with cadaveric pieces ($p=0.010$), using the 3D model singly ($p=0.006$) and the multimodal model ($p<0.001$) all obtained statistically similar results. Therefore, professors should choose the teaching methodology based on their goal and not on the intrinsic qualities of each method.

6. Acknowledgements

Medical School of University Center Christus, UNICHRISTUS, Fortaleza, CE, Brazil.

7. References

1. Cucinotta D, Vanelli M. WHO Declares COVID-19 a Pandemic. *Acta Biomed.* 2020 Mar 19;91(1):157-160. doi: 10.23750/abm.v91i1.9397. PMID: 32191675; PMCID: PMC7569573. Available at: <https://www.mattioli1885journals.com/index.php/actabiomedica/article/view/9397>
2. Marroquín B, Vine V, Morgan R. Mental health during the COVID-19 pandemic: Effects of stay-at-home policies, social distancing behavior, and social resources. *Psychiatry Res.* 2020 Nov;293:113419. doi: 10.1016/j.psychres.2020.113419. Epub 2020 Aug 20. PMID: 32861098; PMCID: PMC7439968. Available at: <https://www.sciencedirect.com/science/article/pii/S0165178120315419?via%3Dihub>
3. Goudeau S, Sanrey C, Stanczak A, Manstead A, Darnon C. Why lockdown and distance learning during the COVID-19 pandemic are likely to increase the social class achievement gap. *Nat Hum Behav.* 2021 Oct;5(10):1273-1281. doi: 10.1038/s41562-021-01212-7. Epub 2021 Sep 27. PMID: 34580440. Available at: <https://www.nature.com/articles/s41562-021-01212-7#citeas>
4. Oliveira João Batista Araujo, Gomes Matheus, Barcellos Thais. A Covid-19 e a volta às aulas: ouvindo as evidências. *Ensaio: avaliação e políticas públicas em educação.* 2022 Jul;28(108):555-578. doi:10.1590/S0104-40362020002802885. Available at: <https://www.scielo.br/j/ensaio/a/KphYGvLvmGSXhBTL5F6zfwf/?lang=pt>
5. Iwanaga J, Loukas M, Dumont AS, Tubbs RS. A review of anatomy education during and after the COVID-19 pandemic: Revisiting traditional and modern methods to achieve future innovation. *Clin Anat.* 2021 Jan;34(1):108-114. doi: 10.1002/ca.23655. Epub 2020 Aug 24. PMID: 32681805; PMCID: PMC7404762. Available at: https://onlinelibrary.wiley.com/doi/full/10.1002/ca.23655?casa_token=k3cVW-jY5_oAAAAA%3A6_PHPywDdKLBn5pK8BXFP8zU6IbyxQKkdADG7Kz9pR2Kk4Cz3GFt5whHJ4hS0zRKOApEgWewWnHGCzI
6. Sora MC, Latorre R, Baptista C, López-Albors O. Plastination-A scientific method for teaching and research. *Anat Histol Embryol.* 2019 Nov;48(6):526-531. doi: 10.1111/ahe.12493. Epub 2019 Oct 1.

PMID: 31573113. Available at: https://onlinelibrary.wiley.com/doi/abs/10.1111/ahe.12493?casa_token=0LPwK3Kkq64AAAAA: 2h6mPMu4QFHsYiIqvEzBmCzpCEW1vTh3U0TpUW87ggTjZauw1kxw6OUeqgYuJXXfdNzvgSwjvm8LT8

7. Hayat Khizar, Qureshi Anas Sarwar, Rehan Sarma, Rehman Tayyab. Plastination - an Innovative Preservative Technique In Anatomy. *Trends in Anatomy and Physiology*. 2018 Mar 10;1(10). doi: 10.24966/TAP-7752/100003. Available at: <http://www.heraldopenaccess.us/openaccess/plastination-an-innovative-preservative-technique-in-anatomy>

8. Chytas D, Piagkou M, Johnson EO, Tsakotos G, Mazarakis A, Babis GC, Nikolaou VS, Kaseta MK, Natsis K. Outcomes of the use of plastination in anatomy education: current evidence. *Surg Radiol Anat*. 2019 Oct;41(10):1181-1186. doi: 10.1007/s00276-019-02270-3. Epub 2019 Jun 15. PMID: 31203398. Available at: <https://link.springer.com/article/10.1007/s00276-019-02270-3>

9. Natali AL, Reddy V, Bordoni B. Neuroanatomy, Corticospinal Cord Tract. 2021 Aug 26. In: StatPearls [Internet]. Treasure Island (FL): StatPearls Publishing; 2022 Jan-. PMID: 30571044. Available at: <https://www.ncbi.nlm.nih.gov/books/NBK554616/>

10. Junior Josival P. Araújo, Galvão Gabriel A. S., Marega Patricia, Baptista Josemberg S., Beber Eduardo H., Seyfert Carlos E. Desafio anatômico: uma metodologia capaz de auxiliar no aprendizado de anatomia humana. *Medicina (Ribeirão Preto)*. 2014;47(1):62-68. doi: 10.11606/issn.2176-7262.v47i1p62-68. Available at: <https://www.revistas.usp.br/rmrp/article/view/80100>

11. Silva Yslaíny Araújo, Júnior Edivaldo Xavier Da Silva, Silva Bruno Nery, Rodrigues Gabriella Pereira, Sousa Gabriella Oliveira, Novaes Wbinayara Alves, Shiosaki Ricardo Kenji, Silva Tarcísio Fulgêncio Alves, Schwingel Paulo Adriano. Confecção de modelo neuroanatômico funcional como alternativa de ensino e aprendizagem para a disciplina de neuroanatomia. *Revista Ibero-Americana de Estudos em Educação*. 2017;12(3):1674–1688. doi: 10.21723/riaee.v12.n.3.2017.8502. Available at: <https://dialnet.unirioja.es/servlet/articulo?codigo=6202866>

12. Saverino D. Teaching anatomy at the time of COVID-19. *Clin Anat*. 2021 Nov;34(8):1128. doi: 10.1002/ca.23616. Epub 2020 May 18. PMID: 32350908; PMCID: PMC7267360. Available at: <https://onlinelibrary.wiley.com/doi/10.1002/ca.23616>

13. Bottino Caroline Fernandes dos Santos. Percepções sobre a educação em anatomia humana pós-pandemia do Covid-19: revisão sistemática da literatura. # Tear: Revista de Educação, Ciência e Tecnologia,. 2021;10(1). doi: 10.35819/tear.v10.n1.a4849. Available at: <https://periodicos.ifrs.edu.br/index.php/tear/article/view/4849>

14. Bücking TM, Hill ER, Robertson JL, Maneas E, Plumb AA, Nikitichev DI. From medical imaging data to 3D printed anatomical models. *PLoS One*. 2017 May 31;12(5):e0178540. doi: 10.1371/journal.pone.0178540. PMID: 28562693; PMCID: PMC5451060.

Available at: <https://journals.plos.org/plosone/article?id=10.1371/journal.pone.0178540>

15. Monfared A, Mitteramskogler G, Gruber S, Salisbury JK Jr, Stampfl J, Blevins NH. High-fidelity, inexpensive surgical middle ear simulator. *Otol Neurotol*. 2012 Dec;33(9):1573-7. doi: 10.1097/MAO.0b013e31826dbca5. PMID: 23047262. Available at: https://journals.lww.com/otology-neurotology/Abstract/2012/12000/High_Fidelity,_Inexpensive_Surgical_Middle_Ear.19.aspx

16. Scawn RL, Foster A, Lee BW, Kikkawa DO, Korn BS. Customised 3D Printing: An Innovative Training Tool for the Next Generation of Orbital Surgeons. *Orbit*. 2015;34(4):216-9. doi: 10.3109/01676830.2015.1049367. Epub 2015 Jun 29. PMID: 26121063. Available at: <https://www.tandfonline.com/doi/abs/10.3109/01676830.2015.1049367>

17. Hochman JB, Rhodes C, Wong D, Kraut J, Pisa J, Unger B. Comparison of cadaveric and isomorphic three-dimensional printed models in temporal bone education. *Laryngoscope*. 2015 Oct;125(10):2353-7. doi: 10.1002/lary.24919. Epub 2015 Aug 8. PMID: 26256951. Available at: https://onlinelibrary.wiley.com/doi/abs/10.1002/lary.24919?casa_token=pIgaCrSJg1MAAAAAA:qage8DHSURfWxvOuj9RdPyX7cdpfupV1ZfGYcz8LO1dUNXSEOp6I9vAqYekNGkj2q06DbbCMDqcSDV0

18. Rose AS, Kimbell JS, Webster CE, Harrysson OL, Formeister EJ, Buchman CA. Multi-material 3D Models for Temporal Bone Surgical Simulation. *Ann Otol Rhinol Laryngol*. 2015 Jul;124(7):528-36. doi: 10.1177/0003489415570937. Epub 2015 Feb 6. PMID: 25662026. Available at: https://journals.sagepub.com/doi/10.1177/0003489415570937?url_ver=Z39.88-2003&rfr_id=ori:rid:crossref.org&rfr_dat=cr_pub%20%20pubmed

19. Ryan JR, Chen T, Nakaji P, Frakes DH, Gonzalez LF. Ventriculostomy Simulation Using Patient-Specific Ventricular Anatomy, 3D Printing, and Hydrogel Casting. *World Neurosurg*. 2015 Nov;84(5):1333-9. doi: 10.1016/j.wneu.2015.06.016. Epub 2015 Jun 20. PMID: 26100167. Available at: <https://www.sciencedirect.com/science/article/abs/pii/S1878875015007640?via%3Dihub>

20. Ahmadlou M, Houba JHW, van Vierbergen JFM, Giannouli M, Gimenez GA, van Weeghel C, Darbanfouladi M, Shirazi MY, Dziubek J, Kacem M, de Winter F, Heimel JA. A cell type-specific cortico-subcortical brain circuit for investigatory and novelty-seeking behavior. *Science*. 2021 May 14;372(6543):eabe9681. doi: 10.1126/science.abe9681. PMID: 33986154. Available at: https://www.science.org/doi/10.1126/science.abe9681?url_ver=Z39.88-2003&rfr_id=ori:rid:crossref.org&rfr_dat=cr_pub%20%20pubmed

21. Saw A. A New Approach to Body Donation for Medical Education: The Silent Mentor Programme. *Malays Orthop J*. 2018 Jul;12(2):68-72. doi: 10.5704/MOJ.1807.015. PMID: 30112135; PMCID: PMC6092528. Available at: <http://morthoj.org/2018/v12n2/silent-mentor-programme.pdf>
22. Jaksa L, Pahr D, Kronreif G, Lorenz A. Development of a Multi-Material 3D Printer for Functional Anatomic Models. *Int J Bioprint*. 2021 Oct 12;7(4):420. doi: 10.18063/ijb.v7i4.420. PMID: 34805598; PMCID: PMC8600298. Available at: <https://ijb.whioce.com/index.php/int-j-bioprinting/article/view/420>
23. Ganguli A, Pagan-Diaz GJ, Grant L, Cvetkovic C, Bramlet M, Vozenilek J, Kesavadas T, Bashir R. 3D printing for preoperative planning and surgical training: a review. *Biomed Microdevices*. 2018 Aug 4;20(3):65. doi: 10.1007/s10544-018-0301-9. PMID: 30078059. Available at: <https://link.springer.com/article/10.1007/s10544-018-0301-9>
24. Papa V, Varotto E, Galli M, Vaccarezza M, Galassi FM. One year of anatomy teaching and learning in the outbreak: Has the Covid-19 pandemic marked the end of a century-old practice? A systematic review. *Anat Sci Educ*. 2022 Mar;15(2):261-280. doi: 10.1002/ase.2162. Epub 2022 Jan 21. PMID: 34890477; PMCID: PMC9011560.
Available at: <https://anatomypubs.onlinelibrary.wiley.com/doi/10.1002/ase.2162>
25. Wilson AB, Miller CH, Klein BA, Taylor MA, Goodwin M, Boyle EK, Brown K, Hoppe C, Lazarus M. A meta-analysis of anatomy laboratory pedagogies. *Clin Anat*. 2018 Jan;31(1):122-133. doi: 10.1002/ca.22934. Epub 2017 Jul 6. PMID: 28612403.
Available at: https://onlinelibrary.wiley.com/doi/abs/10.1002/ca.22934?casa_token=dn9w2ySUuM4AAAAA:QYDrubyY9r7DgpL13ukvEr3mSeBiwTygOBIZ1KgLjXGdf-1mxCrxgwioVQS_Cp34kofd4DUfR0eYz_0